

# ORTHOPEDIC APPROACH TO PECTUS DEFORMITIES: 32 YEARS OF STUDIES

Sydney Abrão Haje<sup>1</sup>, Davi de Podestá Haje<sup>2</sup>

## ABSTRACT

The authors summarize a 32-year experience in the study and in the non-operative approach of pectus carinatum and pectus excavatum. Data of 4,012 patients with pectus deformities were collected from 1977 to January 2009, allowing evaluation on the etiology, pathogenesis and treatment of these deformities. Growth disturbances of anterior chest wall bones and cartilages were detected in imaging studies. Heredity, and biomechanical factors, like respiratory disturbances and scoliosis were noticed in more than 40% of the patients. The method of dynamic remodeling of the thorax – compressive orthoses simultaneously to exercises practice – was indicated in 2453 patients. Concomitant treatment with bending brace was provided in patients with 20° to 52° scoliosis. Of pectus patients with treatment indication, 1717

returned for re-evaluation: 1632 children and adolescents and 85 adults. Good results were seen in 60.6% of children and adolescents and in 27% of adults treated. No scoliosis patient presented curve worsening, and a case of 52° presented an improvement of 20° in the scoliosis with the treatment. Disturbances in the growth of the sternum and costal arches, as well as biomechanical factors related to the pathogenesis of pectus deformities, demonstrate how these deformities are correlated to orthopaedics. Appropriate evaluation of the anterior chest wall and concomitant treatment with bending brace are recommended in the presence of scoliosis. The dynamic remodeling method of the thorax requires a protocol of medical actions for a successful treatment.

**Keywords** - Funnel chest; Thoracic wall. Bone remodeling; Orthotic devices

## INTRODUCTION

**Prevalence and psychological aspects** – Anterior chest wall deformities, known universally as pectus deformities, are often observed in medical practice. Garcia et al.<sup>(1)</sup> report a case of pectus excavatum for every 300 live births and Haje et al.<sup>(2)</sup> describe a case of pectus for every 100 children examined. However, these deformities are usually hidden by patients due to psychological problems, allowing them to remain unknown. The misfortune of having a pectus deformity affect all areas of life. According to Einsiedel and Clausner, psychological effects are larger after 11 years of age, when feelings of embarrassment, social anxiety, shame, limited capacity for activities and communication, negativity, intolerance, frustration, and even depressive reactions are observed<sup>(3)</sup>. On the other hand, appropriate medical support to

patients with a pectus deformity helps to restore the mental health of the patient, returning her or him to normal social life and bringing relief to the family<sup>(4)</sup>. With the large mental suffering that deformities often cause to their carriers, it is necessary that doctors, especially orthopedic surgeons, have knowledge about the formation of the bone and cartilage of the anterior chest wall, the etiology, pathogenesis, and options of treatment for the various types of pectus deformities.

**Anatomopathology and embryological formation of the sternum and costal arches** – Many authors have used the term “suture” in defining the radiolucent lines in the growing sternum<sup>(5-13)</sup>, but it is important to note that sutures exist only in the skull and that the formation and growth of the anterior chest wall are endochondral bone<sup>(14-16)</sup>. Cartilaginous growth plates are present between the growing segments

1 – Pediatric Orthopedist and Psychiatrist, Orthopectus Clinical Center and Asa Norte Regional Hospital.

2 – Doctor in Orthopedics, School of Medicine, University de São Paulo, Ribeirão Preto, SP. Pediatric Orthopedist, Orthopectus Clinical Center. Preceptor, Adult Foot and Pediatric Orthopedics, Federal District Hospital, Brasília, DF.

Correspondence: SMHN Quadra 2 Bloco A Edifício de Clínicas, salas 804-806, Brasília-DF, Brasil. CEP 70710-904. Fax: (61) 3425-1408. E-mail: orthohaje@orthopectus.com.br

We declare no conflict of interest in this article

of the sternum and the costochondral junctions<sup>(17-22)</sup>. The sternum is formed from two longitudinal bands of mesoderm from the shoulder region joining in the craniocaudal direction in a process of chondrification. Costal cartilage from the spine is fused to the sternum in formation and cartilaginous growth plates develop at these sites where the costal cartilage meets with the sternum, and are responsible for sternal growth<sup>(23,24)</sup>. Costal growth plates also exist in the costochondral junction of the costal arches. When approaching the long bones of children and adolescents, the orthopedic surgeon avoids damaging cartilaginous growth plates, knowing that such injury will cause a deformity in the future. Such care, however, seems non-existent in relation to the thorax, to the extent that among the dozens of surgical techniques described for treating pectus deformities, none stated that attention was given to the sternal and costal growth plates<sup>(19)</sup>.

## ETIOLOGY AND PATHOGENESIS

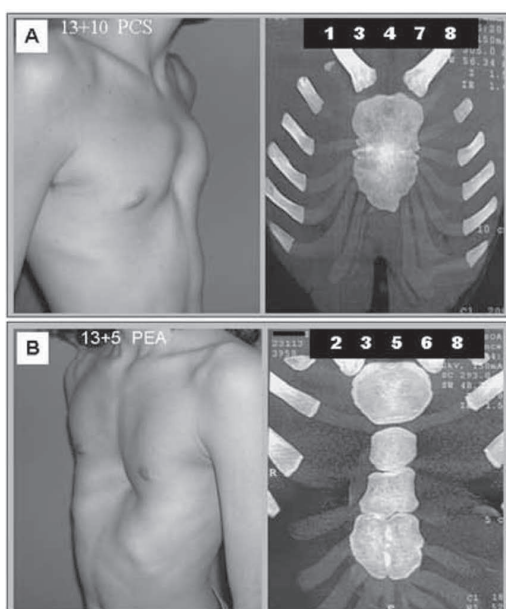
Disturbances in the growth of the bones and cartilage of the anterior chest wall are described in the literature as an etiologic agent<sup>(21,22)</sup>. Therefore, pectus deformities tend to progress naturally at the peak of growth in adolescence<sup>(23,24)</sup>. Biomechanical factors such as respiratory disorders, scoliosis, and kyphosis contribute to the pathogenesis of pectus deformities<sup>(22-24)</sup>.

**Patients of the authors and classification (types of pectus deformities)** – From 1977 to January 2009, we examined 4012 patients with pectus deformities, 73% of which were male and 27% of which were female. As previously described, the deformities were classified according to the anatomical location of the protruding or depressed area<sup>(19,23,25)</sup>. When the deformity was predominantly a protrusion in the sternal region, chondrosternal junction, or costal cartilage adjacent to the sternum, it was classified as pectus carinatum. The exclusive presence of a sternal depression characterized pectus excavatum. We classified pectus carinatum as three basic types according to the anatomic location of the apex of the protrusion: inferior pectus carinatum (IPC), lateral pectus carinatum (LPC) and superior pectus carinatum (SPC). Pectus excavatum was classified according to the extent of depression, as the localized (LPE) or severe (SPE) type. Besides the basic types of pectus, mixed deformities were also detected, and the diagnosis was

always made by the predominant deformity<sup>(23,24)</sup>. In such cases, in addition to the principal diagnosis, the secondary deformity/ies should be noted, such as: SPC + LPE + left LPC, right LPC + LPE, SPE + left LPC, IPC + right LPC, etc. Protrusions of the coastal edge at the bottom of the anterior chest wall, when present, were recorded for proper monitoring and therapeutic definition. Pectus carinatum was the most common in our series, present in 3,111 patients (78%); the diagnosis of IPC was made in 1,785 patients (45%), of LPC in 1,126 (28%), and SPC in 200 (5%). Pectus excavatum was present in 901 patients (22%), and the diagnosis of LPE was made in 529 (13%) and SPE in 372 (9%).

**Imaging tests for etiological analysis** – Profile/oblique radiographs of the sternum were routinely performed and analyzed according to criteria described by Haje et al.<sup>(22)</sup>. Multislice computed tomography (CT) of the anterior chest wall was performed in 94 patients and coronal reconstruction used to better interpret possible disorders involving the formation, growth, and development of the sternum and costal cartilages, that is, to analyze the etiology. The coronal reconstruction of the multislice CT allowed a better visualization of the cartilaginous plates of the sternum and sternal body morphology than the X-ray, also enabling the visualization of the costal cartilages and facilitating the interpretation of disorders involving the formation, growth, and development of the sternum and costal arches. In this test, images suggestive of disturbances in the formation could be detected, such as: 1) fusion and ossification of the xiphoid to the body, 2) lateral irregularity in sternal body morphology, 3) asymmetry of the costal cartilage in the hemithorax, 4) ossification and fusion of the manubrium to the body, 5) irregularity in the cartilaginous growth plates of the sternum, 6) incomplete fusion of the longitudinal bands of embryonic origin of the sternum, 7) fusion of all segments of the sternal body, 8) evident enlargement of the sternal body. Figure 1 depicts these aspects in two patients with idiopathic pectus – a form of pectus detailed below.

**Types of occurrence** – For each patient in this study, the authors investigated possible concomitant skeletal diseases and prior surgical procedures performed on the sternum. Three types of occurrence were detected: pathological, iatrogenic, and idiopathic. The pathological type, which occurs in the presence of



**Figure 1** – Examples of appearances found in the coronal reconstruction of multislice CT of the chest in adolescents with (A) superior pectus carinatum (SPC) and (B) severe pectus excavatum (SPE); both were 13 years old. Appearances include 3) asymmetry of the thorax and costal cartilages, 8) evident enlargement of the sternal body was found in both, while the appearance of 1) ossification and fusion of the xiphoid to the body, 4) ossification and fusion of the manubrium to the body, and 7) fusion of all segments of the sternal body are visible only in (A) and the appearance of 2) lateral irregularity in sternal body morphology, 5) irregularity in the cartilaginous growth plates of the sternum, and 6) incomplete fusion of the longitudinal bands of embryonic origin of the sternum are seen only in (B).

diseases that are associated with growth disorders in general, such as Marfan syndrome, osteogenesis imperfecta, and bone dysplasia, was diagnosed in 11 of our patients (0.3%). The iatrogenic type, due to injury and anatomical perturbation of sternal growth plates, was detected in 22 patients (0.5% of our total cases), in 21 patients after cardiac surgical procedures and one case after neonatal sternal puncture. The idiopathic type, that is, that which affects people who are in good general health, was observed in 3,979 of the patients (99.2%).

**Clinical history and examination for analyzing pathogenesis** – Patients and/or guardians were asked about the presence of other cases in the family (heredity) and biomechanical factors that could influence the growth and development of the anterior chest wall, such as respiratory disorders (asthma, pneumonia, adenoid hypertrophy, sinusitis, allergic rhinitis). Physical and, when necessary, radiological examination were routinely performed to search for deviations

of the spine (exacerbated thoracic kyphoses and/or scolioses). Reports of other cases of pectus in the family occurred in 47% of patients. Previous respiratory disorders such as asthma, pneumonia, adenoid hypertrophy, allergic rhinitis, and sinusitis were reported by 50% of patients. Exacerbation of thoracic kyphosis was present in 14% of cases. Scoliosis of 5° to 19° was detected in 1,685 patients (42% of cases) and between 20° and 52° in 52 patients (1.3% of cases).

## CONSERVATIVE TREATMENT/DR METHOD

Treatment with dynamic compressive orthoses (DTC – dynamic thorax compressor) was first described in 1979 for pectus carinatum<sup>(11,13,26)</sup>. Compressive orthoses with velcro or fasteners on the sides have been described as effective conservative treatment options for children with flexible types of pectus carinatum<sup>(27-31)</sup>. Treatment with DTC orthoses, which have screws on the sides instead of velcro or fasteners and allow for the gradual compression of protruding areas, was described by Haje et al. not only for pectus carinatum, but also for pectus excavatum, starting in 1992<sup>(19,23,32)</sup>. In 2006, the authors synthesized the description of the method by publishing the term “dynamic remodeling (DR) method” to designate the use of DTC orthoses during exercises that promote increased intrathoracic pressure<sup>(33)</sup>. This method involves the balance of forces on the chest: while the orthosis(es) exert dynamic external pressure on protruding or bulging areas, conducting exercises while using of one or two DTC orthoses creates internal pressure on the depressed areas, remodeling the rib cage as a whole.

**Conservative treatment/DR method** – Of the 4,012 patients screened, 2,453 were advised to initiate treatment using the DR method. Of these, 2,278 were children and adolescents, that is, patients with a maximum age of 19 years, and 175 were adults. Orthoses were only prescribed for adult patients who were extremely bothered by the aesthetics of their chest and was always preceded by an explanation of the difficulties of treatment in adulthood. As for growing individuals, the criteria were as follows: in infancy, for patients with SPC (rigid deformity since infancy); in pre-adolescence, for patients with SPE and LPE; and in adolescence, for patients with IPC and LPC (more flexible types of deformities). In infancy, patients with IPC, LPC, SPE, and LPE were

prescribed orthoses only in the presence of a history of frequent respiratory disorder or possibly when the deformity is moderate to severe or progressive. Orthoses were not prescribed for discreet deformities or very young children suffering from IPC, LPC, SPE, and LPE, with no history of respiratory distress. In these cases, they were indicated only for photographic documentation and monitoring.

Clinical photographs of the chest of each patient were performed routinely, always in the same oblique-lateral angle for monitoring. For the evaluation of treatment results, we classified the observed improvement by index of improvement (II) based on analysis of photos, with (3) meaning good or excellent improvement, (2) moderate, (1) discreet, and (0) no improvement.

#### Improvement observed with the DR method

Of the 2,453 patients who were referred to begin dynamic remodeling treatment (2,278 children/adolescents and 175 adults), 1,717 returned for further evaluation, 1,632 children and adolescents, and 85 adults. Children and adolescents comprised 95% of patients who adhered to treatment, while the adults comprised only 5%.

Of the 2,278 children and adolescents that began treatment, 1,632 (71.6% of those who were advised to do so) returned and were followed for a mean follow-up period of one year and seven months (minimum of one month, maximum of 18 years and five months). Table 1 shows the rates of improvement achieved in children and adolescents with the DR method for each type of deformity in absolute values and percentages for each group. The overall percentage of children and adolescents with (3) and (2) improvement was 60.6%.

Of the 175 adults who started treatment, 85 (48.6% among those who were advised to do so) returned for reassessment for a mean follow-up period of one year (minimum one month, maximum four years and five months). Table 2 shows the improvement rates obtained for adults with the DR method for each type of deformity in absolute values and percentages for each group. The overall percentage of adults with (3) and (2) improvement was 27%.

A minimum one month follow-up period was adopted because, with that time, we can often see improvement or even overcorrection<sup>(33)</sup> to flexible carinatum, which does not mean that treatment should be stopped. The shorter the treatment time, the greater

**Table 1** – Index of improvement (II) for treatment by the dynamic method of chest remodeling (DR method) in children and adolescents. Distribution of 1,632 patients who returned for reassessment of treatment according to the type of deformity. The number of patients and II obtained for each type of deformity are expressed by the smaller numbers, and their percentage by larger numbers in bold. Patients with II 3 and II 2 (totals in bold) comprised 60.6% of cases.

Index of improvement	454 LPC	69 SPC	178 LPE	150 SPE	1632 Total
II 3	142 <b>31.3%</b> 388 <b>49.7%</b>	5 <b>7.3%</b>	11 <b>6.2%</b>	2 <b>1.3%</b>	548 <b>33.6%</b>
II 2	139 <b>30.6%</b> 216 <b>27.7%</b>	15 <b>21.7%</b>	40 <b>22.5%</b>	30 <b>20.0%</b>	440 <b>27.0%</b>
II 1	87 <b>19.2%</b> 89 <b>11.4%</b>	29 <b>42.0%</b>	82 <b>46.0%</b>	79 <b>52.7%</b>	366 <b>22.4%</b>
II 0	86 <b>18.9%</b> 88 <b>11.2%</b>	20 <b>29.0%</b>	45 <b>25.3%</b>	39 <b>26.0%</b>	278 <b>17.0%</b>

**Table 2** – Index of improvement (II) for treatment by the dynamic method of remodeling (DR method) in adults. Distribution of 85 patients who returned for reassessment of the treatment according to the type of deformity. The number of patients and II obtained for each type of deformity are expressed by the smaller numbers, and their percentage by larger numbers in bold. Patients with II 3 and II 2 (totals in bold) comprised 27% of cases.

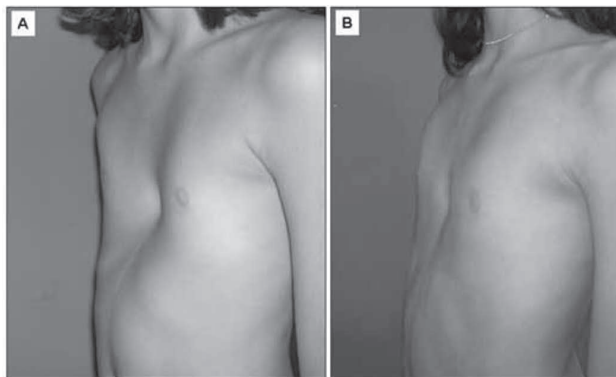
Index of improvement	23 IPC	15 LPC	4 SPC	27 LPE	16 SPE	85 Total
II 3	5 <b>21.7%</b>	-	-	1 <b>3.7%</b>	-	6 <b>7.0%</b>
II 2	6 <b>26.1%</b>	5 <b>33.3%</b>	1 <b>25.0%</b>	4 <b>14.8%</b>	1 <b>6.2%</b>	17 <b>20.0%</b>
II 1	6 <b>26.1%</b>	7 <b>46.7%</b>	3 <b>75.0%</b>	14 <b>51.9%</b>	7 <b>43.8%</b>	37 <b>43.6%</b>
II 0	6 <b>26.1%</b>	3 <b>20.0%</b>	-	8 <b>29.6%</b>	8 <b>50.0%</b>	25 <b>29.4%</b>

the likelihood of recurrence, making basic medical care essential for the proper remodeling of the anterior chest wall. If protrusions are formed at the costal edges or exacerbate the compression of a protruding sternum, a DTC 2 orthosis should be added to the treatment. The removal of the orthosis(es) should be performed gradually and medical discharge should only occur after stabilization of the correction is certain. Example of a patient with pectus excavatum treated successfully can be seen in Figure 2.

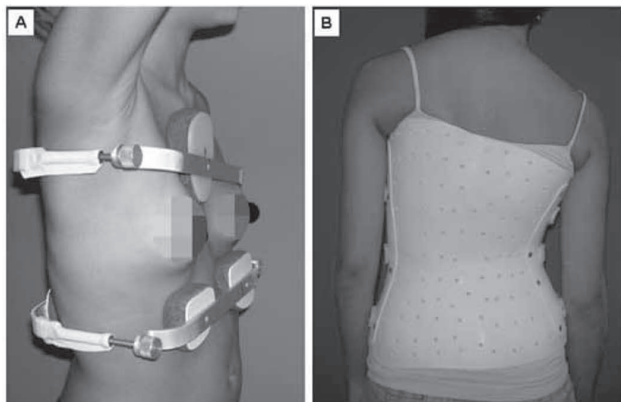
Skin irritation in areas where the DTC pads create pressure was observed to a greater or lesser degree in all patients using the orthosis properly. This irritation can be minimized with proper guidance during periodic medical monitoring and disappears naturally with the interruption or termination of treatment. Overcorrection of the original deformity was detected in 61 cases,

which was corrected in all cases by individual conducts described in a previous publication<sup>(33)</sup>.

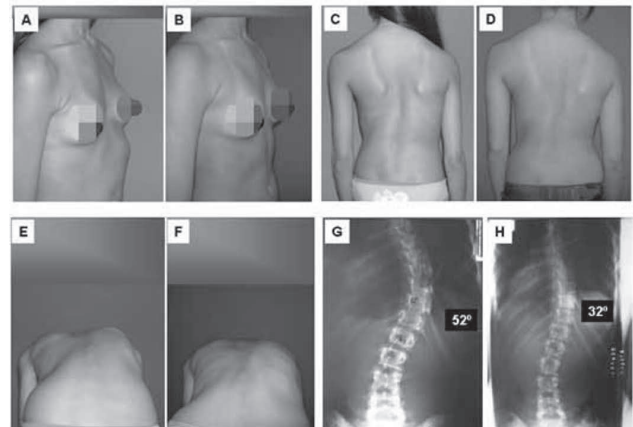
Of the 52 patients with pectus deformities and a scoliosis angle between 20° and 52°, 11 also received concomitant treatment with a Brasília bending brace (BBB)<sup>(34)</sup>. In these cases, the DTC orthosis(es) was/were used for four hours a day, while performing the DR method exercise program, including stretching the spine upright and side bends a greater number of times to the side of the curve that showed an improvement in pre-treatment lateral radiographs, using the BBB for the rest of the day (Figure 3). Of the 11 patients with pectus deformities and a scoliosis angle between 20° and 52° who received a BBB in addition to DR method treatment, eight showed improvement greater than or equal to 5° in the scoliotic curve, and one showed an improvement of 20° (Figure 4).



**Figure 2** – Pre-teen female with localized pectus excavatum, at 10 years of age (A) and one year after treatment by the DR method (B). The improvement (II 3) denotes the assiduity of the patient's use of the DTC 2 orthosis and execution of the exercises, which she reported performing regularly.



**Figure 3** – Patient using DTC orthoses and a Brasília bending brace (BBB)<sup>(34)</sup> for concomitant treatment of pectus deformities and scoliosis.



**Figure 4** – A 13-year-old female patient with 52° severe thoracolumbar dextroconvex scoliosis from T6 to L1, Risser 1 and discreet LPC in the anterior part of her chest, with moderate protrusions of the costal edges (A, C, E, G). She had received surgical indication due to the severity of the curve. Opted to first try concomitant treatment with DTC orthoses and brace shown in Figure 8. She regularly performed the DR method exercises in the DTC orthosis on a daily basis. She used the DTC orthoses about four hours a day and the brace about 19 hours a day. She received three new braces made by plaster mold over the course of treatment. Clinical improvement 33 months after starting treatment, shown in B, D, F, and radiographic evidence showing a reduction of the curve to 32°, shown in H, withdrew the indication for surgery.

### MEDICAL CONDUCTS FOR A SUCCESSFUL DR METHOD

The DR method requires criteria and adequate medical supervision – see the summary of our basic protocol (Appendix 1). Medical supervision should be long-term, since it may take a year or more for a correction to stabilize, depending on how the patient follows the treatment over time. Treatment with DTC I and/or DTC II orthoses should be initiated according to the age and type of deformity, as previously described. The orthoses should be built individually using plaster mold and in reference to detailed prescription, with the shape of the pads marked on the mold and its measures specified in a medical prescription. The anterior and posterior rods should be made of aluminum to allow for adjustments during the progression of treatment as the patient grows and/or the shape of the chest is modified by treatment. The lateral rods must be made of small tubes with nuts on their anterior end. The screws that will be threaded in these tubes should be used as a compression mechanism, for their gradual tightening as the osteocartilaginous structures give impart dynamism to treatment. The

## Appendix 1

**DR method protocol**

- 1) Correct indication of DTC I and/or DTC II orthosis according to age and type of deformity, always using screws as a means of compression.
- 2) Individualized orthoses, made by plaster mold and a detailed medical prescription.
- 3) Raising patient's awareness of the prolonged duration of treatment; success depends on following instructions; continuous use of the orthosis(es) in the first months; daily exercises or at least five days a week.
- 4) Tightening of the screws is controlled by the physician in clinical orthosis placement and follow-up visits; avoid overcorrection; establish additional orthosis if necessary.
- 5) Follow-up visits should be conducted every two or three months in the first year and then every four months.
- 6) Adjustments in the orthosis; monitor growth and changes in the chest with treatment; possible construction of a new orthosis.
- 7) Prescription of exercises, always while wearing the orthosis, taught by a trained physical therapist; not to overdo workload at the gym.
- 8) Prevent severe skin irritation: wearing tight cotton fabric under the orthosis or clean cotton knit covers on the pads; control overcorrection.
- 9) Clinical photographs obtained always using the same angle before and during treatment.
- 10) Physician coordinates the therapeutic process, involving other health professionals such as physical therapists and orthotic technicians.

exercises complement the dynamism of treatment, working the movements of the thoracic cavity and creating internal pressure in the depressed areas of the anterior chest wall. Prior instruction on the DR method must be provided to patients and their caregivers, comparing it to orthodontic treatment, that is, an extended treatment that should gradually remodel the rib cage in order to stabilize the correction and eliminate the risk of relapse. The patient should be instructed to wear the orthosis continuously in the first few months (two to four months for carinatum and six to 12 months for excavatum), even to sleep, removing it only for showering and swimming. This orientation is very important for the patient to adapt to the presence of the orthosis, because the longer the patient is without the orthosis, the more uncomfortable it will be to put it back on and the lower their acceptance of continuous treatment.

The ideal compression of the orthosis should be determined by the physician when consulting the patient about its placement by tightening the screws until the orthosis is firm on the chest of the patient. The patient should be instructed to loosen the orthosis, but to not remove it, in case of

discomfort or pain. After symptoms are relieved, the patient should be instructed to tighten the screws to the degree that was previously determined. Progress in the degree of tightness and compression should occur according to patient's tolerance. In rare cases, medication is indicated for pain control. The medical follow-up visits should be scheduled every two or three months the first year and then every four months. Eventually, the construction of a new orthosis using a new plaster mold may be necessary. An adjustment that is often necessary as the patient grows and the chest changes with treatment is lateral extension. Such an extension is made by opening the angles of the rear rod and of the anterior rod. Decreasing the length of the screws and lateral rods or moving the anterior rod's angle folding forward may be necessary to provide additional compression. Bending often occurs in the middle part of the anterior and/or posterior rods, requiring that the physician prescribe straightening of these parts, as well as their duplication for reinforcement, so that compression can once again be effective. Such modifications and adjustments provide ways of additionally tightening the screws that had completely penetrated the lateral rods. Necessary changes can also be made to the positioning, size, and shape of the pads.

The prescription of exercises while wearing the orthosis is essential. The exercises should be taught and a list created by a trained physical therapist and the patient should perform them daily. Pec deck exercises at the gym should also be prescribed and be performed three times a week, always while the patient is in the DTC orthosis. The prescription should emphasize that such exercises, performed under the supervision of a fitness trainer, does not aim to induce muscle hypertrophy, but the movement of the thoracic cavity, and that therefore the exercise load should not be exaggerated, and should prioritize a program that gradually increases not the load, but the number of repetitions, according to the patient's age. Weight lifting, swimming, or other exercises alone do not correct pectus deformity. They can only occasionally disguise it through muscular hypertrophy. Weight training without concomitant use of a DTC orthosis can aggravate a protruding chest and contribute to its

stiffness. A sternal depression can also become more rigid and have its appearance worsened if there is excessive development of the pectorals. Corrective remodeling of pectus excavatum, therefore, only happens when a compression of the costal edges enhances the increase in intrathoracic pressure caused by exercise. Swimming, however, should be prescribed without the orthosis, for all ages, in freestyle and backstroke – or crawl stroke – in order to maintain chest flexibility and improvement in their physical condition, with consequent better torso posture, helping to fight poor posture, which can aggravate the pectus deformity.

The patient should be instructed to perform the learned exercises at the gym, and on days when the patient does not go to the gym, to perform them at home, always while wearing the orthosis. To minimize skin irritation, tight cotton clothing should be worn under the orthosis or cotton knit covers with elastic around the edges should be made, placed on the pads and changed for clean ones daily. Skin irritation and possible overcorrection are controlled by appropriate medical follow-up, and do not require interruption of treatment. Use of topical medications is rarely necessary, and when this occurs, the patient should be instructed to go two hours without the orthosis, removing the oily cream or ointment with alcohol before wearing it again. Haje and Haje described the measures to be adopted to control overcorrection<sup>(33)</sup>. Clinical photographs should always be taken in the same angle before, during, and after treatment, covering only the torso of the patient. The appropriate archiving of these photos documents the clinical evolution of the case, providing support for interpretation and clinical management, as well as serving as motivation for the patient to continue treatment. Treatment should be conducted by a team composed of a physician, an orthotic technician, and a physical therapist, with the physician managing the entire process.

According to Haje, patients with pectus may have mild and flexible scoliosis and postural kyphosis that improve merely by use of the DR method<sup>(23)</sup>. Our findings suggest that severe scoliosis, between 20° and 52°, when associated with pectus deformities, may benefit from the concomitant treatment of the brace and the DR method, but this requires

further studies for verification. The present study did not aim to detail etiological and pathogenic findings, much less analyze in detail the findings of imaging studies and the results of the concomitant treatment of scoliosis. Its goal is to transmit the authors' experience in addressing pectus deformities, opening up new avenues for research on the subject and make the treatment they are recommending executable by all interested physicians and, in particular, orthopedists.

## FINAL CONSIDERATIONS

Our results concerning the etiology and pathogenesis are highly suggestive of disturbances in the formation, growth, and development of osteocartilaginous structures of the anterior chest wall, demonstrating the link between pectus deformities and orthopedics. The conservative treatment option for pectus deformities is based on the principles of Nicolas Andry, considered “the father of orthopedics,” and the effects of this treatment can be explained by Julius Wolff's law of bone remodeling. Therapeutic forces applied regularly on deformed bones and cartilage may produce a gradual remodeling in a beneficial and corrective direction, and this can be observed especially in the anterior chest wall, which is a flexible region.

The treatment of pectus deformities involves understanding basic orthopedic concepts. Therefore, the nature of pectus deformities is related to orthopedics and its study should be part of the curriculum of orthopedic issues. Simply prescribing an orthosis does not mean treating a pectus deformity. A protocol should be followed to conduct proper and successful treatment.

## ACKNOWLEDGEMENTS

The authors thank the physicians Moacir Silva Neto, Guilherme de Souza e Cássia, Gustavo Reis Alves de Oliveira, Rodrigo Coimbra Batista and Tito Lívio Mundim, for the assistance in the interpretation of the multislice computed tomography demonstrated in this work. They also thank their colleague Rubens Paiva Souza, for his assistance in surveying cases of people with pectus and scoliosis who received concomitant treatment.

## REFERENCES

1. Garcia VF, Seyfer AE, Graeber GM. Reconstruction of congenital chest-wall deformities. *Surg Clin North Am*. 1989;69(5):1103-18.
2. Haje DP, Haje SA, Simioni MA. Prevalência das deformidades *pectus carinatum* e *pectus excavatum* em escolares do Distrito Federal. *Brasília Med*. 2002;39(1/4):10-5.
3. Einsiedel E, Clausner A. Funnel chest. Psychological and psychosomatic aspects in children, youngsters and young adults. *J Cardiovasc Surg (Torino)*. 1999;40(5):733-6.
4. Haje SA, Haje DP. Tratamento conservador e reabilitação de pacientes com deformidades pectus: uma experiência de 29 anos. *Med Reabil*. 2007;26(1):1-6.
5. Bryson V. Development of the Sternum in Screw Tail Mice. *Anat Rec*. 1945;91:119-41.
6. Herdner M. Le Sternum de l'enfant. Etude radiologique das anomalias de son developpement. *Rev Orthop*. 1947;33(6):475-93.
7. Currarino G, Silverman N. Premature obliteration of the sternum sutures and pigeon breast deformity. *Radiology*. 1958; 70(4):352-40.
8. Gabrielsen TO, Ladyman GH. Early closure of the sternal sutures and congenital heart disease. *Am J Roentgenol Radium Ther Nucl Med*. 1963;89:975-83.
9. Fischer KC, White RI Jr, Jordan CE, Dorst JP, Neil CA. Sternal abnormalities in patients with congenital heart disease. *Am J Roentgenol Radium Ther Nucl Med*. 1973;119(3):530-8.
10. Ravitch MM. Congenital deformities of the chest wall and their operative correction. Philadelphia: WB Saunders; 1977.
11. Haje SA, Raymundo JLP. Considerações sobre deformidades da parede torácica anterior e apresentação de tratamento conservador para as formas com componentes de protrusão. *Rev Bras Ortop*. 1979;14(4):167-78.
12. Kuhn JP. The Thorax. In: Silverman FN. Editor. *Caffey's pediatric X-ray diagnosis*. Chicago: Year Book Medical Publishers; 1985. p.1097-9.
13. Haje SA, Antunes EJ, Raymundo JLP, Dourado JN. Pectus carinatum: enfoque atual. *Rev Bras Ortop*. 1988;23(9):257-64.
14. Lees RF, Caldicott JH. Sternal anomalies and congenital heart disease. *Am J Roentgenol*. 1975;124(3):423-7.
15. Ogden JA, Conlogue GJ, Bronson ML, Jensen PS. Radiology of postnatal skeletal development. II. The manubrium and sternum. *Skeletal Radiol*. 1979;4(4):189-95.
16. Wong M, Carter DR. Mechanical stress and morphogenetic endochondral ossification of the sternum. *J Bone Joint Surg Am*. 1988; 70(7):992-1000.
17. Shimomura Y, Wezeman FH, Ray RD. The growth cartilage plate of the rat rib: cellular differentiation. *Clin Orthop Relat Res*. 1973;(90):246-54.
18. Yamasaki K, Inui S. Lesions of articular, sternal and growth plate cartilage in rats. *Vet Pathol*. 1985;22(1):46-58.
19. Haje SA, Bowen JR. Preliminary results of orthotic treatment of pectus deformities in children and adolescents. *J Pediatr Orthop*. 1992;12(6):795-800.
20. Haje SA. Iatrogenic pectus carinatum: a case report. *Int Orthop (SICOT)*. 1995; 19(6):370-73.
21. Haje SA, Bowen JR, Harcke HT, Guttenberg ME, Bacon CR. Disorders in the sternum growth and pectus deformities: an experimental model and clinical correlation. *Acta Ortop Bras*. 1998; 6(2):67-75.
22. Haje SA, Harcke HT, Bowen JR. Growth disturbance of the sternum and pectus deformities: imaging studies and clinical correlation. *Pediatr Radiol*. 1999; 29(5):334-41.
23. Haje SA. Tórax e cintura escapular. In: Hebert SK, Xavier R, Pardini Junior AG, Barros Filho TEP. *Ortopedia e traumatologia: princípios e prática*. 3ª ed. Porto Alegre: Artmed; 2003. p.161-84.
24. Haje SA, Haje DP. Tórax e cintura escapular. In: Hebert SK, Barros Filho TEP, Xavier R, Pardini Junior AG. *Ortopedia e traumatologia: princípios e prática*. 4ª ed. Porto Alegre: Artmed. 2009; p.147-65.
25. Haje SA. Deformidades pectus: novos conceitos e abordagem ortopédica em crianças e adolescentes - 1ª parte. *Rev Bras Ortop*. 1995;30(1/2):75-9.
26. Beirão ME. Tratamento conservador do *pectus carinatum* com uso de órtese. *Rev Bras Ortop*. 1999;34(11/12): 575-8.
27. Egan CJ, Du Bois JJ, Morphy M, Samples, TL, Lindell B. Compressive orthotics in the treatment of asymmetric pectus carinatum: a preliminary report with an objective radiographic marker. *J Pediatr Surg*. 2000;35(8):1183-6.
28. Frey AS, Garcia VF, Brown RL, Inge TH, Ryckman FC, Cohen AP, et al. Nonoperative management of pectus carinatum. *J Pediatr Surg*. 2006;41(1):40-5.
29. Banever GT, Konefal SH, Gettens K, Moriarty KP. Nonoperative correction of pectus carinatum with orthotic bracing. *J Laparoendosc Adv Surg Tech*. 2006;16(2):164-7.
30. Kravarussic D, Dicken BJ, Dewar R, Harder J, Poncet P, Schneider M, et al. The Calgary protocol for bracing of pectus carinatum: a preliminary report. *J Pediatr Surg*. 2006;41(5):923-6.
31. Martinez-Ferro M, Fraire C, Bernard S. Dynamic compression system for the correction of pectus carinatum. *Semin Pediatr Surg*. 2008;17(3):194-200.
32. Haje SA. Deformidades pectus: novos conceitos e abordagem ortopédica em crianças e adolescentes - 2ª parte. *Rev Bras Ortop*. 1995;30(3):143-9.
33. Haje SA, Haje DP. Overcorrection during treatment of pectus deformities with DCC orthoses: experience in 17 cases. *Int Orthop (SICOT)*. 2006;30(4):262-7.
34. Haje SA, Haje DP, Guerra JB, Petrenko JR. Órtese inclinada de uso contínuo e exercícios para tratamento da escoliose idiopática: uma nova proposta. *Brasília Med*. 2008;45(1):10-20.